Scripta Scientifica Medicinae Dentalis, 2025;Online First

ISSN 2367-7236 (Print)
ISSN 2367-7244 (Online)

CASE REPORTS

TREATMENT OF MULTIPLE GINGIVAL RECESSIONS IN THE AESTHETIC ZONE OF THE MAXILLA WITH CORONALLY ADVANCED FLAP WITH A LATERAL APPROACH AND A TUNNEL TECHNIQUE. A CASE REPORT

Irena Georgieva, Zlatina Tsoneva

Department of Periodontology and Dental Implantology, Faculty of Dental Medicine, Medical University of Varna, Bulgaria

ABSTRACT

INTRODUCTION: The presence of multiple recessions in the aesthetic zone of the upper jaw is associated with aesthetic dissatisfaction of the patient and hypersensitivity of the exposed root surfaces. Different surgical methods are indicated for the treatment of such clinical cases, allowing simultaneously complete root coverage of the exposed surfaces and a maximum aesthetic result – matching the colour and equal borders of the mucogingival line. The triangular coronally advanced flap (CAF) demonstrates good aesthetic results and a high percentage of root coverage.

AIM: The purpose of the presented clinical case is to demonstrate the efficacy of the triangular CAF with lateral approach in the therapy of multiple recessions in a patient with high aesthetic requirements.

CASE PRESENTATION: A 35-year-old man with multiple Miller class 1 recessions in the aesthetic zone of maxilla was treated by a triangular CAF procedure with a lateral approach and, additionally, a tunnel technique between the central incisors was applied.

RESULTS: A harmonious gingival margin, complete root coverage, satisfactory aesthetics, and also elimination of hypersensitivity in the cervical area of the treated teeth are shown as a result of this surgical method for therapy of multiple gingival recessions.

CONCLUSION: The presented case demonstrates good aesthetic results and 100% success using the triangular CAF technique in the treatment of multiple gingival recessions and confirms the good prognosis with this technique.

Keywords: *triangular coronally advanced flap, multiple gingival recessions, complete root coverage*

Address for correspondence:
Irena Georgieva
Faculty of Dental Medicine
Medical University of Varna
84 Tzar Osvoboditel Blvd
9002 Varna, Bulgaria
e-mail: dr.irenageorgieva@mail.bg

Received: January 3, 2025
Accepted: January 19, 2025

INTRODUCTION

A Gingival recession (GR) is a mucogingival defect that affects all ages, but is predominantly diagnosed in elderly individuals (1). It is defined as the distance of proliferation of gingival margin in apical direction in relation to the cementoenamel junction (CEJ) of the tooth (2,3,4). Thus, the CEJ is the guiding criteria in planning the surgical therapy for root coverage.

© The Author(s) 2025. This is an open access article distributed under the Creative Commons Attribution License (CC BY 4.0), which permits unrestricted use, distribution and reproduction in any medium, provided the original work is properly cited.

Gingival recessions can generally affect all teeth or groups of teeth, and can be localized vestibularly, lingually, or proximally on the dental surfaces of a single tooth (5). They are most frequently observed on the facial or on the proximal root surfaces of the teeth. Thus, they lead to localized or generalized exposure of the root surfaces, which can be associated with aesthetic dissatisfaction of the patient due to clinical crown lengthening, especially when affecting the front teeth. In addition, it may be associated with hypersensitivity to thermal and tactile irritants, also appearance of non-carious cervical lesions, erosion or abrasion in the cervical area of the root, and fear of tooth loss from the patient's point of view (6,7). Gingival recessions can be a result of anatomical, physiological, traumatic, or pathological factors (8,9). For the diagnosis of GRs, the classification systems proposed by Miller (10) and Cairo (11) are the most frequently used (12).

In patients with aesthetic requirements and multiple recessions present, a one-stage minimally invasive surgical technique is preferred, resulting in efficient and predictable complete coverage of the exposed root surface without residual cicatrix, match in colour, and equal thickness to the adjacent gingival tissues (13,14).

If we have an adequate amount of keratinized gingiva (KG) apically to the GRs (adequate amount of height and thickness), the preferred surgical method of choice is a coronally advanced flap (CAF) (13,15). In case of an inadequate amount or a lack of KG tissues apically from the exposed root surface, as well as in non-carious cervical lesions, the use of CAF in combination with a connective tissue graft (bilaminar technique) is preferred (16,17,18).

At present, in the therapy of multiple GRs, the CAF described by Zucchelli and De Sanctis in 2000 is the most widely used one (13). A triangular envelope CAF without releasing vertical incisions is used. Usually the flap includes, mesially and distally, at least one tooth adjacent to the teeth affected by GRs. The literature review reveals that this method achieves good results in both the treatment of multiple recessions in distal and frontal regions of the dentition (19,20).

The technique has two approaches:

1. Lateral approach – this is the first original variant of the technique, which allows the correction of GRs in the entire quadrant (from the central incisor to the mesial surface of the first molar) (19), and
2. Frontal approach – a technique for simultaneous treatment of GRs affecting the central and lateral incisors on both sides of the arch (20).

The choice of one of the two approaches depends on whether the canine in a specific clinical case is affected by GR. When we have a GR with a depth of ≥ 1 mm, then there are indications for the lateral approach. When the mucogingival defects affect only the incisors in healthy tissues around the canine or the recession is < 1 mm, the frontal approach is indicated (21).

AIM

The purpose of the presented clinical case is to prove the efficacy of envelope triangular CAF, simultaneously with lateral and frontal approach, for complete root coverage in the treatment of multiple recessions in the maxillary region with a maximally aesthetic result – appropriate colour and thickness of the tissues similar to the characteristics of the adjacent teeth.

CASE PRESENTATION

A 35-year-old male patient came to the University Medical and Dental Center in Varna for a therapy of multiple GRs in the aesthetic zone of the maxilla. The patient complained about aesthetic dissatisfaction in the zone of the anterior teeth in the upper jaw after previous orthodontic treatment, as well as mild hypersensitivity when consuming cold foods and drinks. The patient did not report any systemic diseases, any allergies, regular medication intake, any harmful habits, or occlusal trauma. The patient was a non-smoker. There was no history of traumatic brushing (22).

During the clinical intraoral examination, complete periodontal status was taken (probing depth, level of gingival margin, depth of the gingival recessions, KG width, tooth mobility). A dental status was also taken. No anatomical, pathological, and developmental defects were present. Gingival recessions

were recorded facially in the area of teeth #11, #21, #22, #23, and #24 (Fig. 1). The depth of GRs was recorded using a UNC 15 periodontal probe, and the level of CEJ and the edge of the gingival margin were used as reference points (2).

Radiographic examination proved the absence of interdental alveolar bone loss (Fig. 3).

Thus, the patient was diagnosed with class 1 GRs according to the Miller's classification (9) and class 1 according to the Cairo's classification (10).

Fig. 1. Intraoral preoperative view.

The depth of GRs was as follows: for tooth #11 it was 3 mm, for tooth #21 – 3 mm, for tooth #22 – 2 mm, for tooth #23 – 1 mm, and for tooth #24 – 3 mm (Fig. 2). The GRs did not go apically from the mucogingival junction and no clinical attachment level (CAL) loss was diagnosed on the interproximal tooth surfaces. The height of interdental papillae was preserved (23). Apical to the edge of the gingival margin, the width of the KG tissues was measured from the gingival margin to the level of the mucogingival junction using again a UNC 15 periodontal probe. Accordingly, the available width of KG apical to the respected teeth was as follows: for tooth #11 it was 5 mm, tooth #21 – 4 mm, tooth #22 – 6 mm, tooth #23 – 6 mm, and tooth #24 – 4 mm. There was no mobility of the examined teeth.

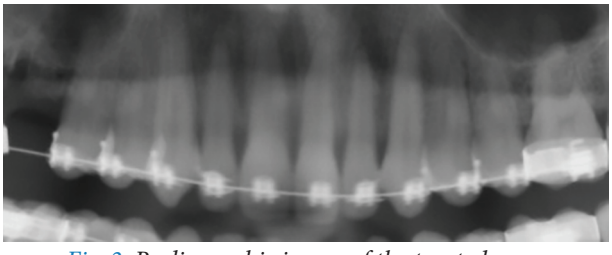

Fig. 3. Radiographic image of the treated area.

An envelope triangular CAF was indicated for the treatment of the present multiple recessions (24). The details of the upcoming surgical intervention were explained to the patient – he was aware of the need for it, the prognosis and the possible risks that accompanied it, and he signed an informed consent.

	18	17	16	15	14	13	12	11	21	22	23	24	25	26	27	28
Mobility	0	0		0	0	0	0	0	0	0	0	0	0	0	0	0
Implant																
Furcation																
Bleeding on Probing		■				■	■ ■									
Plaque																
Gingival Margin	2 2 2	3 1 0		0 0 2	2 0 2	1 1 2	3 0 2	1 -3 1	2 -3 1	1 -2 1	1 -1 1	2 -3 1	2 0 2	2 0 1	2 1 2	3 2 2
Probing Depth	2 2 2	3 1 1		1 1 2	2 1 2	1 1 2	3 1 2	1 1 1	2 1 1	1 1 1	1 1 1	2 2 1	2 1 2	2 1 2	2 2 2	3 2 2

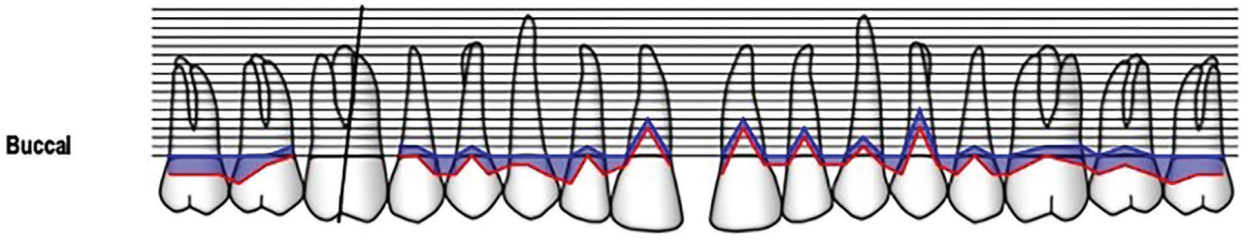

Fig. 2. Initial periodontal status.

TREATMENT

A non-surgical periodontal therapy consisting of precise removal of dental calculus and dental plaque, and polishing of the hard dental tissues was performed before the surgical procedure. The patient was instructed on personal oral hygiene and maintenance of adequate plaque control (O'Leary plaque index < 10%). The modified Stillman technique was recommended for tooth brushing in the area of GRs (25).

Before starting the mucogingival surgery, the treatment site was anaesthetized with local terminal anaesthesia using Septanest (4% articain with 1:100 000 epinephrine).

The triangular envelope CAF design involved a series of horizontal oblique paramarginal incisions in the region of the interdental papillae passing into intrasulcular incisions on the vestibular surface of the affected teeth. All oblique paramarginal incisions were directed to the central axis of the flap passing through the middle of the maxillary canine. The central papilla and the papilla distal to tooth #11 were tunnelized using a papilla elevator. Due to the fact that tooth #25 was not affected by GR, in this clinical case and this technique, one single vertical releasing incision distal to tooth #24 was used (Fig. 4).

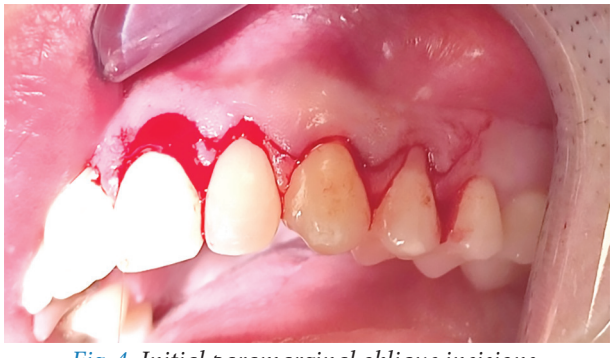

Fig. 4. Initial paramarginal oblique incisions.

Thus, the surgical papillae would subsequently be moved coronally and horizontally, as the papillae on the mesial side of the central axis of the flap would be rotated in a mesial direction and those on the distal side of the central axis – in a distal direction.

A split-thickness flap was elevated in the area of the surgical papilla, using sharp dissection. Apically to the recessions, where the intrasulcular incisions were done, the flap tissues were elevated in full thickness using a small periosteal elevator with the aim to preserve the full thickness of the keratinized tissues in this area and subsequent successful coverage of the exposed avascular root surface. The central papilla and the papilla distally to tooth # 11 were tunnelized using papilla elevator. The flap was elevated in full thickness until at least 3 mm of vestibular alveolar bone located apically to the facial bony dehiscence was visible. After that the flap was continued again in split thickness, cutting the periosteum at the base of the flap through a deep incision so that the blade was oriented parallel to the alveolar bone. A superficial incision was done, then there was cutting through the muscles insertions superficially under the flap tissues and under the central papilla and the papilla distal to tooth #11 to allow the passive replacement of the flap in coronal direction for complete root coverage (Fig. 5).

Fig. 5. Elevation of split-full-split thickness flap.

The superior labial frenulum was cut internally using both incisions. The exposed root surfaces were carefully debrided using mini Gracey 5/6 curettes, avoiding the area adjacent to the anatomical bony dehiscence to prevent damage to the healthy connective tissue fibres embedded in the root cementum. The anatomical papillae were then de-epithelialized using a surgical blade #15C or microblade and surgical microscissors. The de-epithelialized anatomical papillae served as vascular connective tissue beds on which the surgical papillae of the flap would subsequently be replaced. The flap tissues were passively moved approximately 1 mm coronally to the CEJ, with all surgical papillae resting on the de-epithelialized anatomical papillae, and the flap was sutured with sling sutures by grasping two surgical papil-

lae with one sling suture. The first sling suture was done through the most distal papilla, and the second one – through the most mesial papilla. In the area of the vertical incision, loop sutures were done using monofilament threads 6/0 (Fig. 6).

Fig. 6. Suturing of the flap tissues using sling sutures.

Postoperative instructions were given to the patient to abstain from mechanical plaque control in the zone of the treated area for 7–10 days until the sutures were removed. For chemical plaque control, chlorhexidine 0.12% was prescribed to rinse the oral cavity 2–3 times per day for the next 14 days. Anti-inflamatory and analgetic agents were also prescribed.

The sutures were cut out after 10 days and follow-up visits were scheduled every 2 weeks for the next 3 months. After removing the sutures, the patient was instructed to use a postoperative ultrasoft toothbrush in the surgically treated zone and apply a roll tooth brushing method, moving the filaments of the toothbrush in an apico-coronal direction (26).

RESULTS

Two months after surgery, a satisfactory aesthetic result was observed and complete root coverage of the exposed root surfaces was seen (Fig. 7).

After 6 months, the periodontal status was registered again and the depth of GRs, probing depth, CAL, and width of KG buccally were measured. The measured levels were compared to the baseline from the initial status.

The absence of GRs in teeth #11, 21, 22, 23, 24 and complete root coverage were established. A clinical attachment gain was demonstrated in all treated teeth, as well as a keratinized tissue gain in teeth #21 and #23.

Fig. 7. Two months after surgery.

A harmonious gingival margin, a slightly visible presence of scars, and keratinized tissue gain were shown as a result of this CAF with lateral approach and tunnel technique for treatment of multiple recessions.

DISCUSSION

The proposed surgical technique is based on biological principles that ensure a better healing result, both in terms of aesthetics and complete root coverage. The use of an envelope flap improves the blood supply to the marginal tissues of the flap, which is impaired when vertical incisions are used. Preservation of the interdental keratinized tissues ensures marginal stability of the flap, more precise suturing, and better aesthetics between the surgically treated zone and the adjacent gingival tissues.

Elevation of flap in split-full-split thickness provides greater thickness of flap tissues that cover the avascular exposed root surface. This improves the trophicity of the flap tissues and reduces the risk of marginal tissue dehiscence postoperatively (27), guaranteeing better predictability of the procedure, the possibility of complete root coverage, and stability of the results over time (28).

CONCLUSION

The presented clinical case demonstrates good aesthetic results and 100% success using the triangular CAF procedure for the treatment of multiple GRs. This case confirms the good prognosis with this surgical method.

REFERENCES

1. Georgieva I. Prevalence of Gingival Recessions in the Aesthetic Zone of Maxilla in Bulgarian Population. Int J Sci Res. 2018;8(7):631-6. doi: 10.21275/ART2019515.
2. Kim DM, Neiva R. Periodontal soft tissue non-root coverage procedures: a systematic review from the

AAP regeneration workshop. J Periodontol. 2015; 86(S2):S56–S72. doi: 10.1902/jop.2015.130684.

3. Tatakis DN, Chambrone L, Allen EP, Langer B, McGuire MK, Richardson CR, Zabalegui I, Zadeh HH. Periodontal soft tissue root coverage procedures: a consensus report from the AAP Regeneration Workshop. J Periodontol. 2015;86(2):S52-5. doi: 10.1902/jop.2015.140376.

4. Cortellini P, Bissada NF. Mucogingival conditions in the natural dentition: Narrative review, case definitions, and diagnostic considerations. J Periodontol. 2018; 89 Suppl 1:S204-S213. doi: 10.1002/JPER.16-0671

5. Chapple ILC, Mealey BL, Van Dyke TE, Bartold PM, Dommisch H, Eickholz P, et al. Periodontal health and gingival diseases and conditions on an intact and a reduced periodontium: Consensus report of workgroup 1 of the 2017 World Workshop on the Classification of Periodontal and Peri-Implant Diseases and Conditions. J Periodontol. 2018;45 Suppl 20:S68-S77. doi: 10.1111/jcpe.12940.

6. Sangnes G, Gjermo P. Prevalence of oral soft and hard tissue lesions related to mechanical tooth cleaning procedures. Community Dent Oral Epidemiol. 1976; 4(2):77-83. doi: 10.1111/j.1600 0528.1976.tb01607.x.

7. Rotundo R, Mori M, Bonaccini D, Baldi C. Intra- and inter-rater agreement of a new classification system of gingival recession defects. Eur J Oral Implantol. 2011 Summer;4(2):127-33.

8. Jati AS, Furquim LZ, Consolaro A. Gingival recession: its causes and types, and the importance of orthodontic treatment. Dental Press J Orthod. 2016 Jun;21(3):18-29. doi: 10.1590/2177-6709.21.3.018-029.oin.

9. Georgieva I. Etiology of gingival recessions – a literature review. Scr Sci Med Dentalis. 2019; 5(2):7-12. doi:10.14748/ssmd.v5i2.5970.

10. Miller PD Jr. A classification of marginal tissue recession. Int J Periodontics Restorative Dent. 1985;5(2):8-13

11. Cairo F, Nieri M, Cincinelli S, Mervelt J, Pagliaro U. The interproximal clinical attachment level to classify gingival recessions and predict root coverage outcomes: an explorative and reliability study. J Clin Periodontol. 2011 Jul;38(7):661-6. doi: 10.1111/j.1600-051X.2011.01732.x.

12. Georgieva I. Classification of gingival recessions - a review. Varna Med Forum. 2019;8(2):122-30. doi:10.14748/vmf.v8i2.5936.

13. Zucchelli G, De Sanctis M. Treatment of multiple recession-type defects in patients with esthetic demands. J Periodontol. 2000 Sep;71(9):1506-14. doi: 10.1902/jop.2000.71.9. 1506.

14. Zucchelli G, Mele M, Mazzotti C, Marzadori M, Montebugnoli L, De Sanctis M. Coronally advanced flap with and without vertical releasing incisions for the treatment of multiple gingival recessions: a comparative controlled randomized clinical trial. J Periodontol. 2009 Jul;80(7):1083-94. doi: 10.1902/jop.2009.090041.

15. Zucchelli G, Stefanini M, Ganz S, Mazzotti C, Mounssif I, Marzadori M. Coronally advanced flap with different designs in the treatment of gingival recession: A Comparative controlled randomized clinical trial. Int J Periodontics Restorative Dent. 2016;36(3):319-27. doi: 10.11607/prd.2698.

16. Zucchelli G, Amore C, Sforza NM, Montebugnoli L, De Sanctis M. Bilaminar techniques for the treatment of recession-type defects. A comparative clinical study. J Clin Periodontol. 2003 Oct;30(10):862-70. doi: 10.1034/j.1600-051x.2003.00397.x.

17. Zucchelli G, Gori G, Mele M, Stefanini M, Mazzotti C, Marzadori M, Montebugnoli L, De Sanctis M. Non-carious cervical lesions associated with gingival recessions: a decision-making process. J Periodontol. 2011 Dec;82(12):1713-24. doi: 10.1902/jop.2011.110080.

18. Georgieva I. Bilaminar technique for treatment of multiple Miller's class III recession defects in the mandibular frontal area. A case report. Scr Sci Med Dentalis. 2020;6(1):30-7. doi:10.14748/ssmd.v6i1.6455.

19. Ribeiro FS, de Morais-Camillo JA, Fernandes JM, Pires JR, Zuza EP, Pontes AE. Multiple marginal tissue recession treated with a simplified lateral sliding flap technique. Case Rep Dent. 2014;2014:432960. doi: 10.1155/2014/432960.

20. Zucchelli G, De Sanctis M. The coronally advanced flap for the treatment of multiple recession defects: a modified surgical approach for the upper anterior teeth. J Int Acad Periodontol. 2007 Jul;9(3):96-103.

21. Yu S, Shiau H. Treatment of multiple adjacent gingival recession. Dent Rev. 2024;4(2):100091. doi: 10.1016/j.dentre.2024.100091.

22. Addy M. Tooth brushing, tooth wear and dentine hypersensitivity-are they associated? Int Dent J. 2005;55(4 Suppl 1):261-7. doi: 10.1111/j.1875-595x.2005.tb00063.x.

23. Georgieva I, Peev S, Gerova T, Miteva M, Bazitova-Zlateva M. Interdental papillae height assessment in the aesthetic zone of maxilla. Scr Sci Med Dentalis. 2017;3(2):11-6. doi: 10.14748/ssmd.v3i1.2179.

24. Zucchelli G, Stefanini M, Ganz S, Mazzotti C, Mounssif, I et al. Coronally Advanced Flap with Different Designs in the Treatment of Gingival Recession: A Comparative Controlled Randomized Clinical Trial. Int J Periodontics Restorative Dent. 2016;36(3):319-27. doi: 10.11607/prd.2698.

25. Rajwani AR, Hawes SND, To A, Quaranta A, Rincon Aguilar JC. Effectiveness of Manual Toothbrushing Techniques on Plaque and Gingivitis: A Systematic Review. Oral Health Prev Dent. 2020 Oct 2;18:843-54. doi: 10.3290/j.ohpd.a45354.

26. Weng L, Wen J, Cui G, Liang J, Pang L, et al. Comparison of modified bass, rolling, and current toothbrushing techniques for the efficacy of plaque control – A randomized trial. J Dentistry 2023;135:104571. doi.org/10.1016/j.jdent.2023.104571

27. Wennstrom JL, Zucchelli G. Increased gingival dimensions. A significant factor for successful outcome of root covearaege procedures? A 2-year prospective clinical study. J Clin Periodontol. 1996; 23(8):770-7. doi: 10.1111/j.1600-051x.1996.tb00608.x

28. Georgieva I. Coronally advanced flap technique for root coverage in the aesthetic zone of upper jaw. J IMAB. 2020 Jul-Sep;26(3):3267-70. doi: 10.5272/jimab.2020263.3267.